

Adenomatoid hyperplasia of the soft palate

Munir Nashashibi¹ and George Habib^{2*}

¹Department of Pathology, Laniado Hospital, Netanya, Israel

²Department of Medicine, Laniado Hospital, Netanya, Israel

Adenomatoid hyperplasia (AH) of minor salivary gland is a rare finding. It usually occurs in the buccal area a usually seen as a lesion. It is usually asymptomatic but could associate with vocal swelling.

Case presentation

15 year old healthy girl that was referred by her family physician for asymptomatic lesion on the soft palate, just above the uvula, measuring 1x1 cm in diameter. Patient had excisional biopsy of the lesion showing hyperplastic minor salivary gland tissue, some of surrounded with skeletal muscle, with prominent mucous component.

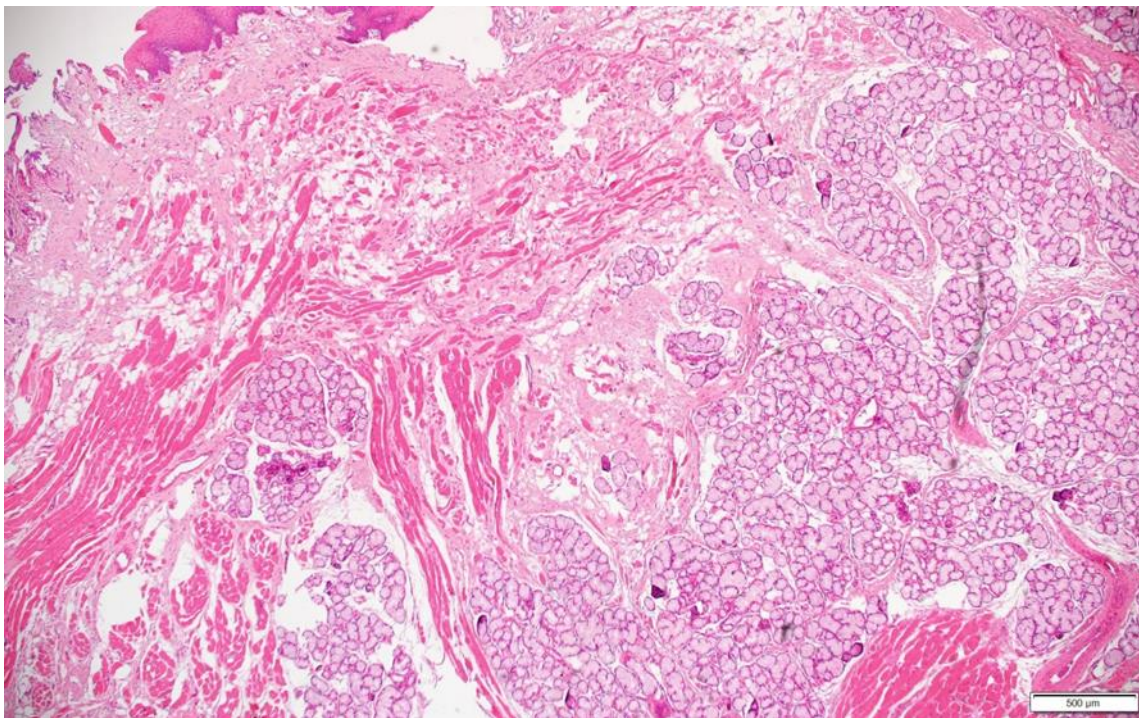


Figure 1. EKG consistent with rapid atrial fibrillation.

*Correspondence: George Habib, Department of Medicine, Laniado Hospital, Netanya, Israel, Tel: 506265591; E-mail: gshabib@gmail.com

Rec: Jan 10, 2020; Acc: Jan 20, 2020; Pub: Jan 24, 2020

J Clin Med Imag. 2020;3(1):119

DOI: 10.36879/JCMI.20.00119

Copyright ©2020 The Author(s). This is an open-access article distributed under the terms of the Creative Commons Attribution 4.0 International License (CC-BY).